



Citation for published version:

Teo, EC, Hailbkova, S, Winkelstein, B, Welch, W, Holsgrove, T & Cazzola, D 2017, 'Morphometric Analysis of Human Second Cervical Vertebrae (Axis)', *Journal of Spine*. <https://doi.org/10.4172/2165-7939.1000399>

DOI:

[10.4172/2165-7939.1000399](https://doi.org/10.4172/2165-7939.1000399)

Publication date:

2017

Document Version

Publisher's PDF, also known as Version of record

[Link to publication](#)

Publisher Rights

CC BY

University of Bath

Alternative formats

If you require this document in an alternative format, please contact:
openaccess@bath.ac.uk

General rights

Copyright and moral rights for the publications made accessible in the public portal are retained by the authors and/or other copyright owners and it is a condition of accessing publications that users recognise and abide by the legal requirements associated with these rights.

Take down policy

If you believe that this document breaches copyright please contact us providing details, and we will remove access to the work immediately and investigate your claim.

Morphometric Analysis of Human Second Cervical Vertebrae (Axis)

Teo EC^{1*}, Haiblikova S², Winkelstein B³, Welch W³, Holsgrove T⁴ and Cazzola D⁵

¹School of Mechanical and Aerospace Engineering, College of Engineering, Nanyang Technological University, Singapore

²Department of Biomechanics and Medical Instruments, Czech Technical University in Prague, Czech Republic

³Department of Bioengineering, School of Engineering and Applied Sciences, University of Pennsylvania, USA

⁴Department of Engineering, University of Exeter, UK

⁵Department of Health, University of Bath, UK

*Corresponding author: E.C. Teo, School of Mechanical and Aerospace Engineering, College of Engineering, Nanyang Technological University, Singapore, Tel: +65 67905529; Fax: +65 67924062; E-mail: mecteo@ntu.edu.sg

Rec Date: Dec 08, 2017; Acc Date: Dec 12, 2017; Pub Date: Dec 16, 2017

Copyright: © 2017 Teo EC, et al. This is an open-access article distributed under the terms of the Creative Commons Attribution License, which permits unrestricted use, distribution, and reproduction in any medium, provided the original author and source are credited.

Abstract

Possessing an odontoid process and unique superior articular facets, the axis vertebra morphometry significantly differs from morphometry of other cervical vertebrae. The fractures of axis, especially its dens, are very common and surgeries highly risky. Knowledge of the axis dimensions is essential not only for preclinical studies, diagnosis of spinal cord diseases, planning of the surgeries but also for correct selection and insertion of surgical instruments or vertebral implants design. Many quantitative studies of the second cervical vertebra have been performed, yet still lacking the area parameters determination and precision of three-dimension *in vivo* measurement. Vertebral dimensions are reported to vary among populations, although there are very little studies examining Caucasian specimen.

This study aims to provide three-dimensional *in vivo* morphometric analysis of the axis vertebra as well as comparison to the previous studies. The clinically relevant vertebral dimensions were measured on the three-dimensional model reconstruction of CT scans providing high accuracy. Five human second cervical vertebrae were investigated (Caucasian males) and linear, area and angular dimensions were measured.

The data on vertebral body dimensions were best fitting Doherty and Naderi measurement. The vertebra body anterior height was established to be 26.2 mm and the posterior height 21.4 mm. The dens parameters were similar to those presented by Doherty. Doherty also reported large variation in the dens sagittal angle which was observed in the present study as well. The dens height was determined to be 17.8 mm which is significantly greater compared to the previous studies. The smallest height among specimens was reported to be 17.0 mm. The smallest antero-posterior or transverse diameter of the dens measured was the upper depth, 9.4 mm. The smallest and biggest areas of dens were measured to be 79.0 mm² and 121.6 mm². The superior articular facet area with mean value 211.2 mm² was observed to be significantly bigger than the inferior area, 141.2 mm². The mean sagittal angle of the inferior facet area was assessed to be 42.1° and the mean frontal angle of the superior articular facet 69.3°. The parameters of articular facets measured by Xu correspond to the present study. Due to the vertebral body enlargement in the inferior part of vertebra, the spinal canal superior depth, 18.0 mm, was observed to be bigger than its inferior depth, 16.2 mm. In case of the spinal canal depth, Sengul measured values considerably greater than other studies. However, Singla, Gosavi and Xu presented the parameters very similar to the present study. Spinal canal width was measured to be 24.4 mm supporting the measurement done by Sengul which is 24.7 mm.

The measured vertebral dimensions can be used either for development of instrumentation, preclinical planning of surgeries, implant design or as the reference values for evaluation and diagnosis of various clinical conditions.

Keywords: Cervical vertebrae; Spinal canal; Odontoidectomy; Caucasian males

Introduction

The axis vertebra features an atypical shape and both its anatomical and biomechanical properties are unique. Diseases of the spinal column at cervical and lumbar region are among the most frequent syndromes [1]. It is also reported that the fractures of the dens axis account for nearly the third of cervical vertebrae fractures [2,3]. However, surgeries in this region are highly risky for possible damage to aorta or other adjacent vital structures [4-6]. Thus, the dimensions

of instrumentations and their insertion need to respect anatomical features of the vertebra. Not only for treatment of vertebral diseases and instabilities, but also for diagnoses, the knowledge of the exact vertebral dimensions is crucial. As the ethnical differences in the vertebral dimensions has been reported, it is also necessary to distinguish the patient origin [7-9]. Regarding all these statements, it is obvious that wide range of precise and clinically important parameters corresponding to the specimen ethnical origin is necessary.

Due to its frequent fractures, the main interest of previous studies was the odontoid process and the vertebral body [10-13]. The parameters such as dens axis high, width, depth and vertebral body height were examined as they are important factors for odontoid screw

fixation, transoral odontoidectomy, anterior and posterior stabilization of odontoid process. Although, the area of dens, which seems to be more relevant for screw design as well as stress distribution, is yet to be determined. Other studies focused more on the spinal canal parameters which play an important role in stenosis and intraspinal tumours diagnosis [14-16]. Some of the researches devoted themselves to measure the pedicle parameters for transpedicular screw fixation [8,17-22]. The previous studies obtained morphometric parameters either from CT scans or radiographs [10,16,17,23] or by direct measurement performed on cadavers [15,18,24-27].

This study aims to provide clinically relevant parameters of second cervical vertebra. Twenty-seven linear, area and angular parameters are measured using a novel three-dimensional *in vivo* technique of morphometric analysis. For further comparison purposes, the measured parameters definition follows the previous studies. The reference study defining most of the parameters is the study done by Xu [18], then Sengul and Singla [15,27]. The measured vertebral dimensions can be used either for development of instrumentation, preclinical planning of surgeries, implant design or as the reference values for evaluation and diagnosis of various clinical conditions.

Materials and Methods

Study included five specimens with no evidence of spinal disease (Caucasian males, average age 61 years). CT scans of the axis vertebra were provided by The Shape Spine Biomechanics and Spine Pain Research Lab, Uni of Pennsylvania, US. The images were obtained using CT Scanner [Siemens Somatom Definition Flash] with 0.6 mm slice thickness and 512 × 512 matrix. The morphometric analysis of vertebra was focused on the odontoid process, vertebral body, articular facets and vertebral canal.

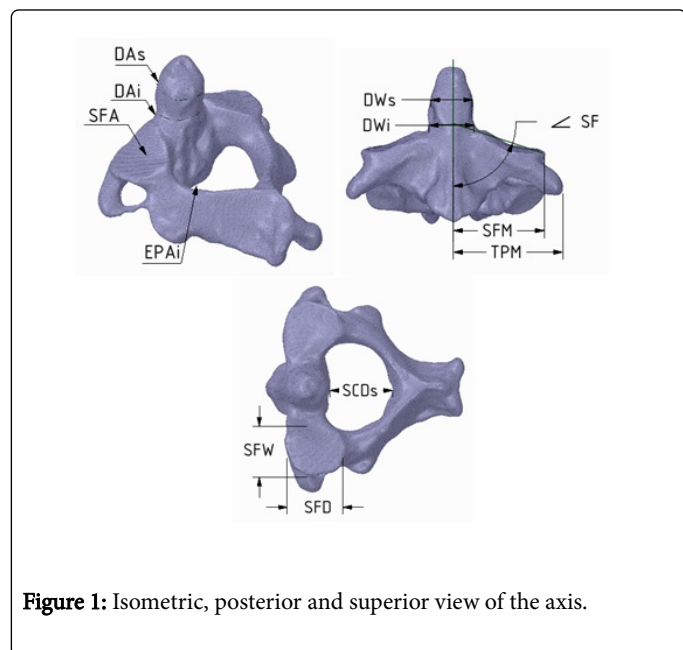


Figure 1: Isometric, posterior and superior view of the axis.

The method of the model reconstruction was followed as described in the previous study [28]. The three-dimensional model was reconstructed from CT images using 3D image data processing software ScanIP Academic, [Synopsys Inc.]. The recursive gaussian filter for model smoothening was applied with sigma 0.8 in all axes. The three-dimensional model was subsequently imported into ANSYS

SpaceClaim where the vertebra orientation and all the measurements were performed.

Body		
Vertebral body depth	VBD	The widest AP dimension of the inferior end-plate of the vertebral body [18].
Vertebral body width	VBW	The widest transverse dimension of the inferior end-plate of the vertebral body [18].
Vertebral body area	VBA	The area of the inferior end-plate of the vertebral body.
Vertebral body anterior height	VBHa	From the anterior inferior edge to the superior border, defined by superior line of the superior articular facet; measured in the anterior midline [18].
Vertebral body posterior height	VBHp	Vertically in the posterior midline of the vertebral body from the posterior inferior edge to the superior border [18].
End-plate lip height		The difference between anterior and posterior vertebral body height [24].
Dens		
Dens superior width	DWs	The transverse diameter of the dens measured on frontal plane at the level of upper curvature.
Dens inferior width	DWi	The transverse diameter of the dens measured on frontal plane at root of the dens.
Dens superior depth	DDs	Antero-posterior diameter at the level of DAWs.
Den inferior depth	DDi	Antero-posterior diameter at the level of DAWi.
Dens area superior	DAs	Area of the dens axis at the level of DAWs.
Dens area inferior	DAi	Area of the dens axis at the level of DAWi.
Dens height	DH	From superior-most point of the dens to the superior line of the superior articular facet [18].
Dens vertical angle	<DV	Between the axis of the dens and the inferior surface of the vertebral body [18].
Dens sagittal angle	<DS	Sagittal angle of the dens axis with the respect to the frontal plane [15].
Facet area and transverse process		
Superior articular facet to the midline	SFM	The most lateral edge of left/right superior articular facet to the midline [27].
Transverse process to the midline	TPM	From the most lateral point of left/right transverse process to the midline [27].
Superior articular facet depth	SFD	The maximum antero-posterior dimension of the left/right superior articular facet [18].
Inferior articular facet depth	IFD	The maximum antero-posterior dimension of the left/right superior articular facet [18].

Superior articular facet width	SFW	The maximum transverse dimension of the left/right superior articular facet [18].
Inferior articular facet width	IFW	The maximum transverse dimension of the left/right superior articular facet [18].
Superior articular facet area	SFA	Area of left/right superior articular facet measured on the plane parallel to the facet surface.
Inferior articular facet area	IFA	Area of left/right inferior articular facet measured on the plane parallel to the facet surface.
Superior articular facet angle	<SF	Frontal angle of left/right superior articular facet with respect to the sagittal plane [18].
Inferior articular facet angle	<IF	Sagittal angle of left/right inferior articular facet surface with respect to the transverse plane.
Spinal canal		
Spinal canal width	SCW	The maximum transverse diameter of spinal canal [18].
Spinal canal superior depth	SCDs	The maximum AP diameter of the spinal canal measured at the superior inlet of the canal [18].
Spinal canal inferior depth	SCDi	The maximum AP diameter of the spinal canal measured at the inferior outlet of the canal [18].

Table 1: The definition of measured parameters.

Each vertebra was orientated prior to the measurement to follow the definitions of parameters from previous studies. For coordinate system definition, two planes were established. The first vertical plane was defined by three points; the point in the axis of dens on its anterior surface, in the middle of antero-inferior edge of the vertebral body and in the middle of the tip of spinous process.

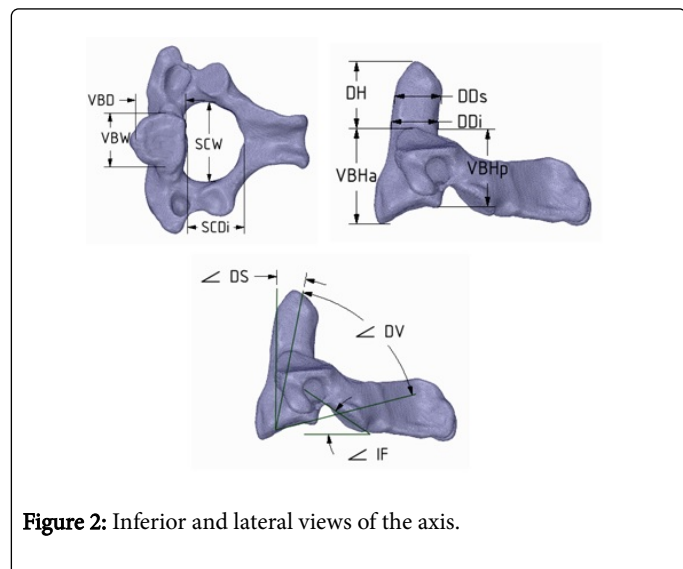


Figure 2: Inferior and lateral views of the axis.

The horizontal plane was defined by the three lowest points of the vertebra; one belonging to the inferior edge of the vertebral body, and other two situated either on the inferior articular facets or two ends of spinous process.

The vertebral orientation was followed by measurement. Each specimen was examined by one researcher obtaining eighteen linear, five area and four angular parameters. The exact definition of parameters is provided in Table 1 supported by graphical interpretation shown in Figures 1 and 2.

As a reference study for definition of parameters served the study done by Xu [18], in case of some parameters missing, studies by Doherty, Sengul and Singla were followed [15,24,27].

Results and Discussion

Eighteen linear, five areas and four angular parameters were measured. Based on five investigated specimens, mean value, range and standard deviations were calculated. Table 1 summarizes all measured parameters for each specimen. The results were then compared to the previous studies [11,15,18,24-27].

On the vertebral body, anterior and posterior height as well as inferior end-plate dimensions were investigated. Parameters of the inferior end-plate included width, depth and area. Vertebral body data is provided in Table 2.

Vertebral Body	Vertebral body depth	Vertebral body width	Vertebral body inferior area	Vertebral body anterior height	Vertebral body posterior height
	VBL	VBW	VBAi	VBHa	VBHp
Mean	17.4	18.2	243.7	26.2	21.4
SD	0.9	1.6	33.3	1.4	0.9
Maximum	18.8	19.4	288	28	22.6
Minimum	16.4	16.2	203	24.2	20

Table 2: Measured dimensions of the vertebral body.

Vertebral body anterior height is in all cases bigger than posterior height (Figure 3), due to the vertebral wedging. Figure 3 also compares the inferior end-plate width and depth. Although the width is mostly bigger than the depth, values do not differ significantly and for specimen 2 and 3 they are almost the same.

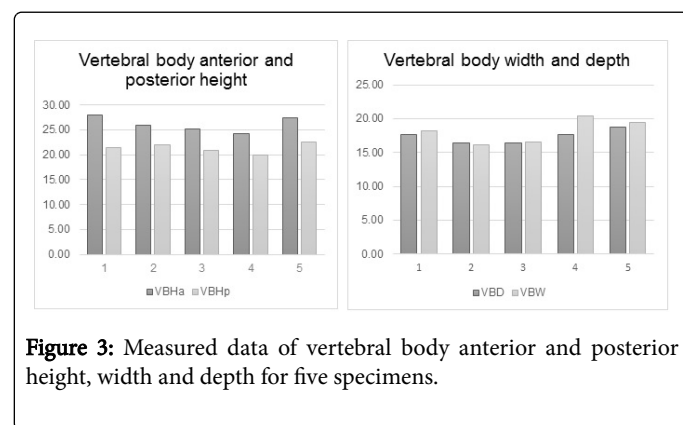


Figure 3: Measured data of vertebral body anterior and posterior height, width and depth for five specimens.

Vertebral body measurement including vertebral body length, width, anterior and posterior height was previously performed by Gosavi [26], Singla [27], Naderi [11], Xu [18] and Dohery [24]. In Figure 4, the comparison to the present study is shown. For the

comparison purposes, only mean value and standard deviation of parameters from the present study is taken into consideration. The results of the present study are the most resemble to the measurement done by Naderi and Doherty. Unlike the values of the depth and width

which seems to be rather similar, the anterior and posterior height varies significantly. This can be due to the inaccurate definition of the line of superior border separating the body from the dens.

Dens	Dens superior width	Dens inferior width	Dens superior depth	Dens inferior depth	Dens superior area	Dens inferior area	Dens height	Dens vertical angle	Dens sagittal angle
	DWs	DWi	DDs	DDi	DAs	DAi	DH	DV	DS
Mean	11.5	11.2	12.4	9.9	111.5	89.4	17.8	59.7	12.7
SD	0.8	0.8	1.5	0.9	16.7	10.2	1.0	10.7	6.7
Maximum	12.4	12.6	13.8	13.4	126.9	121.6	19.8	78.1	19.6
Minimum	10.0	10.4	9.4	9.9	79.0	89.4	17.0	48.1	0.8

Table 3: Measured parameters of the dens.

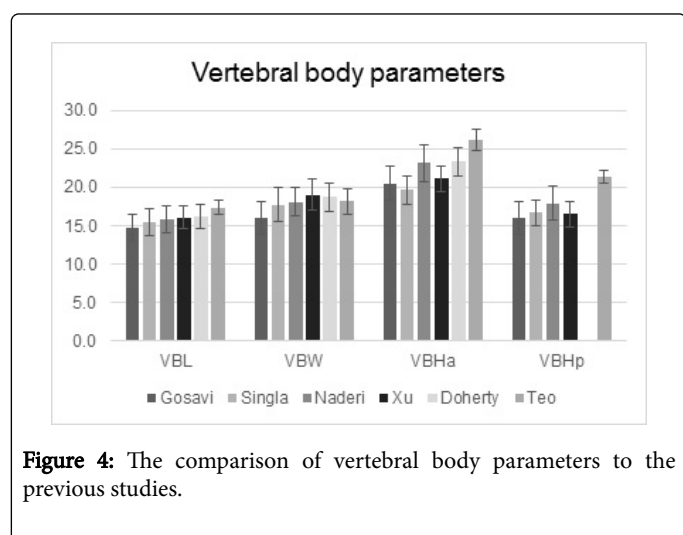


Figure 4: The comparison of vertebral body parameters to the previous studies.

The definition of dens parameters was complicated as the features of shape described in previous studies were not observed. Xu and Doherty measured two transverse parameters of the dens [18,24]; maximum width located at the upper part of the dens and minimum width located at the dens root. However, for the investigated specimens, the width of the dens at the upper curvature was sometimes smaller than the one measured at its root (Figure 1). The widths are thus called superior and inferior. The dens depth and cross-sectional area were then assessed at the level of previous measurement of widths. Table 3 shows the results of the measurement.

The smallest antero-posterior or transverse diameter of the dens was measured 9.4 mm as the upper depth of the dens. Smallest and biggest areas of dens axis were measured to be 79.0 mm² and 121.6 mm². The measured values of depth and width of the dens are compared to studies done by Xu and Doherty in Figure 5. The results of the present study are more similar to Doherty's values. The comparison of high of dens is shown in Figure 5.

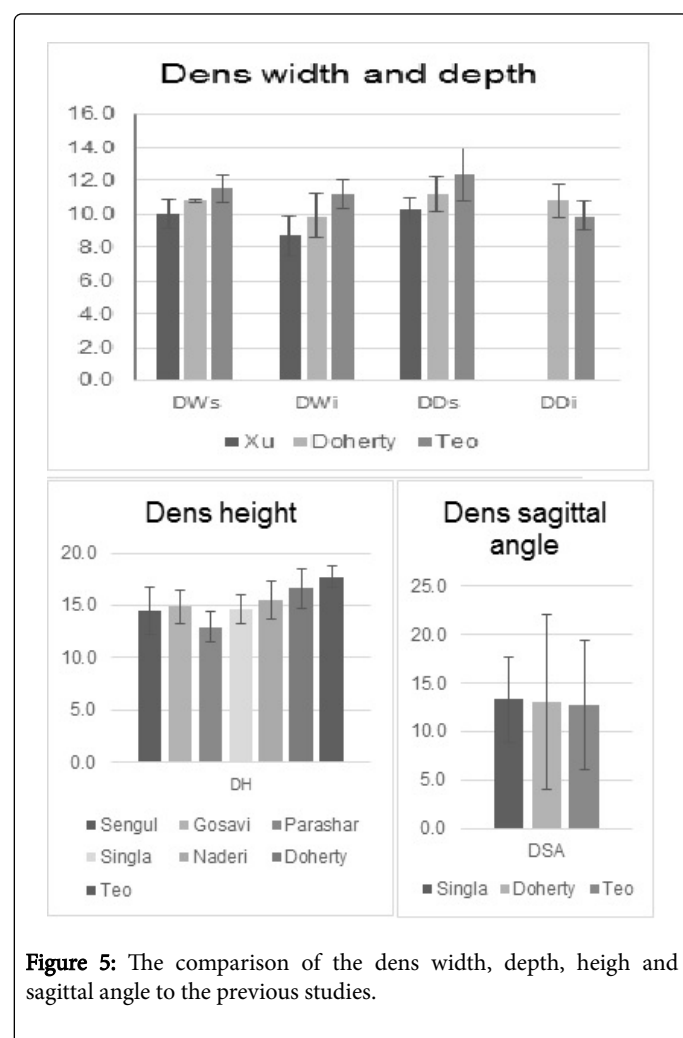


Figure 5: The comparison of the dens width, depth, height and sagittal angle to the previous studies.

The result of present study follows the Doherty's results. Dens axis high was determined to be 17.8 mm which is significantly greater compared to the previous studies. The smallest height among specimens was reported to be 17.0 mm. There is a significant difference between the specimens in dens axis vertical angle as well as sagittal

angle represented by large standard deviation (Table 3). The large variation in sagittal angle of dens has already been reported by Doherty with values ranging from -2° to 42°. However, when compared to the study performed by Doherty and Singla, mean values of dens axis sagittal angle are very similar (Teo 12.7°, Doherty 13.0° and Singla 13.3°).

Superior and inferior articular facet areas were assessed for five linear, two area and two angular parameters. Linear parameters consist of width and depth of superior and inferior facet and the distance of the most lateral end of superior facet to the midline. The results are shown in Tables 4 and 5.

Superior articular facet	Superior articular facet to the midline		Superior articular facet depth			Superior articular facet width			Superior articular facet area			Superior articular facet angle		
	SFM		SFD			SFW			SFA			SF		
	R	L	R	L	A	R	L	A	R	L	A	R	L	A
Mean	24.5	25.0	16.5	16.8	16.7	17.2	16.3	16.7	212.7	209.6	211.2	69.1	69.5	69.3
SD	1.5	0.8	1.9	1.4	1.6	1.0	1.8	1.2	29.0	34.5	31.7	0.9	3.9	2.3
Maximum	26.0	26.0	18.2	18.6	18.1	18.2	18.6	17.6	249.6	256.7	240.7	69.9	74.9	72.4
Minimum	21.6	24.0	13.0	14.4	13.7	15.4	13.6	14.5	162.4	154.1	158.2	67.5	65.0	66.3

Table 4: Measured parameters of the superior articular facet.

Unlike other studies, width and depth measurement of the facets was performed in horizontal or vertical direction as defined by Xu

[18]. Areas of superior and inferior facet was estimated by outlining the facet area edge on the plane parallel to the surface of the facet.

Inferior articular facet & transverse process	Transverse process to the midline		Inferior articular facet depth		Inferior articular facet width		Inferior articular facet area			Inferior articular facet angle		
	TPM		IFL		IFW		IFA			IF		
	R	L	R	L	R	L	R	L	A	R	L	A
Mean	29.8	32.4	14.9	15.0	12.5	13.1	140.2	142.1	141.2	42.4	41.8	42.1
SD	1.0	2.2	2.4	0.8	2.4	1.9	35.6	25.9	30.7	7.7	4.8	5.72
Maximum	31.8	35.2	18.8	15.8	15.6	15.6	179.4	164.8	171.2	51.4	47.6	33.3
Minimum	29.2	30.2	11.4	13.6	8.6	9.8	78.2	93.2	85.7	32.3	34.3	48.6

Table 5: Measured parameters of the inferior facet area.

The results showed that superior facet area with mean value 211.2 mm² is significantly larger than inferior facet area, 141.2 mm² (Figure 6). The comparison of superior facet width and depth to the study done by Xu is shown in Figure 6. The results of the present study are slightly smaller than those measured by Xu. It is most likely due to the different technique of measurement. In the present study, only the surface of the facet areas was taken into consideration by estimation of facet edge, whereas Xu measured the parameters by caliper thus establishing the parameter from the edge of the articular process. The superior facet angle with respect to the sagittal plane was similar for all the specimens ranging between 65.0° and 74.9° with the mean value 69.3°. Unlike the inferior facet angle with respect to the frontal plane with large range, minimum value 32.3° and maximum 51.4°. When compared to the previous studies, the superior facet angle measurement is the most similar to study performed by Xu.

inferior outlet antero-posterior diameters were significantly different. The inferior outlet depth was always smaller than the superior outlet depth because of the vertebral body enlargement at the inferior area (Figure 7).

Spinal canal	Spinal width	Spinal canal superior depth	Spinal canal inferior depth
	SCW	SCDs	SCDi
Mean	24.4	18.0	16.2
SD	1.0	1.9	1.6
Maximum	25.4	20.1	18.0
Minimum	23.0	14.6	13.2

Table 6: Parameters of the spinal canal.

Spinal canal was measured for three linear parameters; width and superior and inferior depth (Table 6). For definition of spinal canal depth, two parameters were established as the superior inlet and

The spinal canal width measurement, mean value 24.4 mm, follows results of the study done by Sengul which is 24.7 mm [15]. Although in case of spinal canal depth, Sengul measured values considerably greater than other studies. However, Singla, Gosavi and Xu presented the parameters very similar to the present study [18,26,27].

Conclusion

In the present study, five Caucasian male specimens were examined to assess the parameters of vertebral body, dens, spinal canal and articular facets of the axis vertebra. Linear, angular and area parameters were obtained. Dimensions were measured on three-dimensional model reconstructed from CT scans which provide high accuracy. The technique also allowed a simple measurement of area either on the cutting plane or on the surface of the bone. Although area parameters provide more relevant values for further clinical investigation, no previous studies evaluating the area parameters were found.

The results and their further comparison showed several significant features. Vertebral body anterior height (26.2 mm) was found to be bigger than the posterior height (21.4 mm), this was also supported by the results of previous studies. Vertebral body width (18.2 mm) was observed to be larger than the vertebral body depth (17.4 mm), although for some specimens these parameters were rather similar. Unlike the previous studies, the dens axis was assessed by parameters located at the upper part and at the root of the dens. Although the mean value of dens superior width (11.5 mm) was bigger than the one measured at the root (11.2 mm), the upper values were not always bigger. The present study determined mean value of dens axis height to be 17.8 mm which is significantly greater value compared to the previous studies. There were large variations in dens sagittal and vertical angle, as previously reported by Doherty [24]. Although the mean values of the sagittal angle (12.7°) compared to studies done by Doherty and Singla were similar. Furthermore, results showed that superior facet area (211.1 mm²) was significantly larger than inferior facet area (141.16 mm²). Because of the vertebral body enlargement in the inferior part of vertebra, the spinal canal superior depth (18.0 mm) was observed to be bigger than its inferior depth (16.2 mm).

The data presented in the study are meant to contribute to creation of the precise database of vertebral dimensions of Caucasian population. The results can serve as reference values used for diagnosis of various clinical conditions. Moreover, measured dimensions can be used in modelling of the axis for improved implant or surgical instrumentation design and related FEM analysis. They may also be helpful for preclinical planning to avoid or minimize surgical complication such as vertebral artery injuries or damage to other vital structures.

Acknowledgements

This research is supported by School of Mechanical and Aerospace Engineering of Nanyang Technological University, Singapore [Rekindle Seed Grant].

References

1. Mayer F, Börm W, Thomé C (2008) Degenerative cervical spinal stenosis. *Dtsch Arztebl Int* 105: 366-372.
2. Clark CR, White AA (1985) Fractures of the dens: A multicentre study. *J Bone Joint Surg Am* 56: 1340-1348.
3. Ochoa G (2005) Surgical management of odontoid fractures. *Injury* 36: 54-64.
4. Madawi AA, Case ATH, Solanki GA, Tuite G, Veres R, et al. (1997) Radiological and anatomical evaluation of the atlantoaxial transarticular screw fixation technique. *J Neurosurg* 86: 961-68.
5. Wright NM, Lauryssen C (1998) Vertebral artery injury in C1-2 transarticular screw fixation: Results of a survey of the AANS/CNS

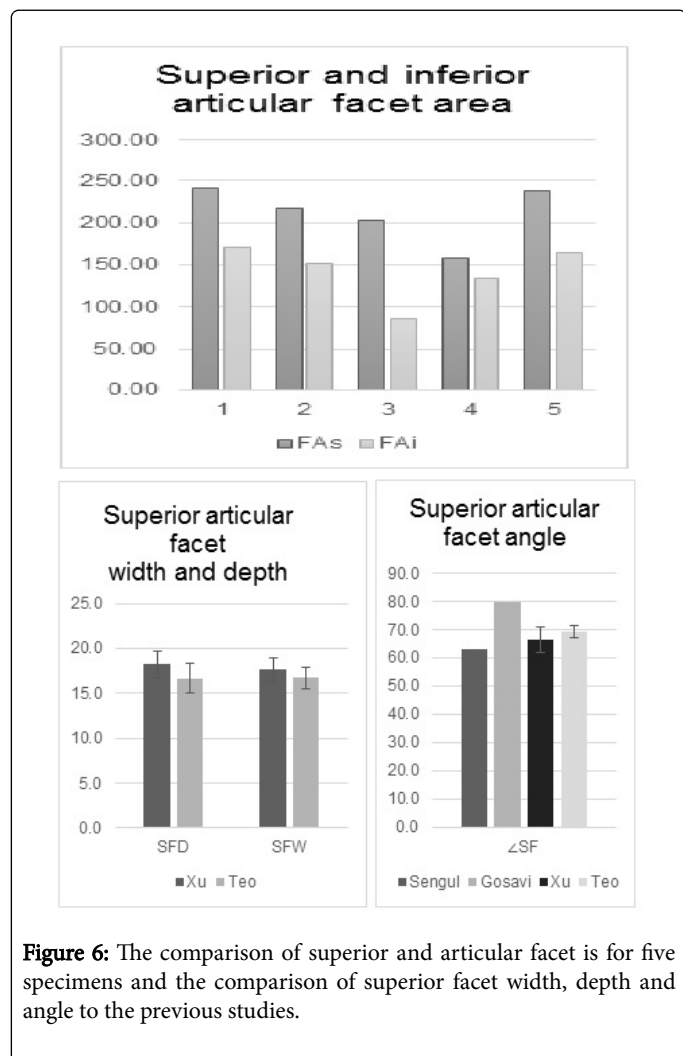


Figure 6: The comparison of superior and articular facet is for five specimens and the comparison of superior facet width, depth and angle to the previous studies.

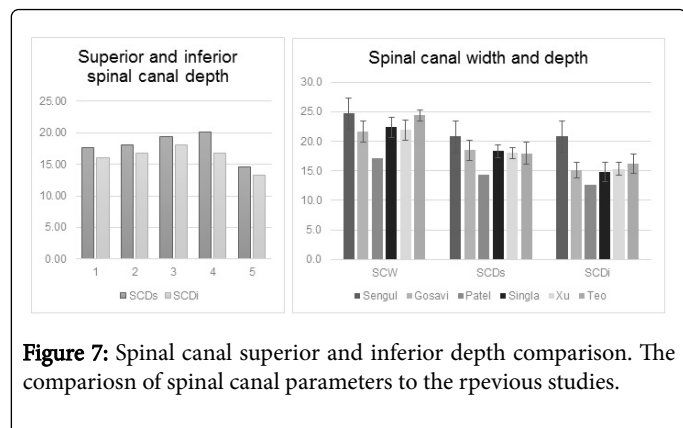


Figure 7: Spinal canal superior and inferior depth comparison. The comparison of spinal canal parameters to the previous studies.

- section on disorders of the spine and peripheral nerves. *J Neurosurg* 88: 634-640.
6. Gupta S, Goel A (2000) Quantitative anatomy of the lateral masses of the atlas and axis vertebrae. *Neurol India* 48: 120-125.
 7. Tan SH, Teo EC, Chua HC (2004) Quantitative three-dimensional anatomy of cervical, thoracic and lumbar vertebrae of Chinese Singaporeans. *Eur Spine J* 13: 137-146.
 8. Yusof MI, Ming LK, Abdullah MS (2007) Computed tomographic measurement of cervical pedicles for transpedicular fixation in a Malay population. *J Orthop Surg* 15: 187-190.
 9. Chen C, Ruan D, Wu C, Wu W, Sun P, et al. (2013) CT morphometric analysis to determine the anatomical basis for the use of transpedicular screws during reconstruction and fixations of anterior cervical vertebrae. *PLoS ONE* 8: e81159.
 10. Heller JG, Alson MD, Schaffler MB, Garfin SR (1992) Quantitative internal dens morphology. *Spine* 17: 861-866.
 11. Naderi S, Arman C, Guvencer M, Korman E, Senoglu M, et al. (2006) Morphometric analysis of the C2 body and the odontoid process. *Turkish Neurosurgery* 16: 14-18.
 12. Schaffler MB, Alson MD, Heller JG, Garfin SR (1992) Morphology of the dens. A quantitative study. *Spine* 17: 738-743.
 13. Nucci RC, Seigal S, Merola AA, Gorup J, Mroczek KJ, et al. (1995) Computed tomographic evaluation of the normal adult odontoid. Implications for internal fixation. *Spine* 20: 264-270.
 14. Gupta SK, Roy RC, Srivastava A (1982) Sagittal diameter of the cervical canal in normal Indian adults. *Clin Radiol* 33: 681-685.
 15. Sengul G, Kadioglu HH (2006) Morphometric anatomy of the atlas and axis vertebrae. *Turkish Neurosurgery* 16: 69-76.
 16. Evangelopoulos DS, Kontovazenitis P, Kouris S, Zlatidou X, Benneker LM, et al. (2012) Computerized tomographic morphometric analysis of the cervical spine. *The Open Orthopaedics Journal* 6: 250-254.
 17. Kathole MA, Joshi RA, Herekar NG, Jadhav SS (2012) Dimensions of cervical spinal canal and vertebrae and their relevance in clinical practice. *International Journal of Recent Trends in Science and Technology* 3: 54-58.
 18. Xu R, Nadaud MC, Ebraheim NA, Yeasting RA (1995) Morphology of the second cervical vertebra and the posterior projection of the C2 pedicle axis. *Spine* 20: 259-263.
 19. Karaikovic EE, Daubs MD, Madsen RW, Gaines RW Jr (1997) Morphologic characteristics of human cervical pedicles. *Spine* 22: 493-500.
 20. Lu J, Ebraheim NA, Yang H, Heck BE, Yeasting RA (1998) Anatomic considerations of anterior transarticular screw fixation for atlantoaxial instability. *Spine* 23: 1229-1236.
 21. Panjabi MM, Shin EK, Chne NC, Wang JL (2000) Internal morphology of human cervical pedicles. *Spine* 25: 1197-1205.
 22. Kayalioglu G, Erturk M, Varol T, Cezayirli E (2007) Morphometry of the cervical pedicles as a guide for transpedicular screw fixation. *Neurol Med Chir* 47: 102-108.
 23. Sharma RM, Pruthi N, Pandey P, Dawn R, Ravindranath Y, et al. (2005) Morphometric and radiological assessments of dimensions of Axis in dry vertebrae: A study in Indian population. *Indian J Orthop* 49: 583-588.
 24. Doherty BJ, Heggeness MH (1995) Quantitative anatomy of the second cervical vertebra. *Spine* 20: 513-517.
 25. Gosavi S, Swamy V (2012) Morphometric study of the axis vertebra. *Eur J Anat* 16: 98-103.
 26. Parashar R, Chauhan S, Saxena D, Meena SL (2014) A morphometric study of atlas and axis vertebrae in Rajasthan population. *J of Evolution of Med and Dent Sci* 3: 15497-15506.
 27. Singla M, Goel P, Ansari MS, Ravi KS, Khare S (2015) Morphometric analysis of axis and its clinical significance – An anatomical study of Indian human axis vertebrae. *J Clin Diagn Res* 9: 4-9.
 28. Teo EC, Holsgrove T, Haiblikove S (2017) 3D morphometric analysis of human vertebrae C3-T3 using CT images reconstruction. *J Spine* 6: 391.